

Influence of lumbar intervertebral disc height and geometry of the articular plateau surface on disc pathologies

Effect of disc height and articular plateau surface on disc pathologies

Volkan Kızılgöz¹, Muhammet Bora Uzuner²

¹ Department of Radiology, Faculty of Medicine, Erzincan Binali Yıldırım University, Erzincan

² Department of Anatomy, Faculty of Medicine, Bandırma Onyedi Eylül University, Balıkesir, Turkey

Abstract

Aim: This study aimed to investigate the relationship between the height of the intervertebral disc space and disc pathologies and the effect of differences in the vertebral articular surface on disc pathologies with regard to age groups.

Material and Methods: A total of 754 patients examined by magnetic resonance imaging were reassessed in terms of the height of the anterior, middle, and posterior intervertebral disc space and the vertebral articular plateau surface type of the L4–L5 and L5–S1 intervertebral disc levels.

Results: All L4–L5 intervertebral disc heights of all patients with any disc pathology were significantly lower than those in the normal group. For the L5–S1 disc level, anterior, middle, and posterior intervertebral disc heights of all patients with disc pathologies were significantly lower than those of the subjects without any disc pathology. There was a significant difference in the L4–L5 levels in discs with irregular articular plateau surfaces among patients in the age group of 25–40 years and for all patients as compared with normal and pathological discs. At the L5–S1 level, there were more disc pathologies in the flat and irregular articular plateaus in the group of patients older than 40 years.

Discussion: The heights of the intervertebral disc spaces were significantly smaller in patients with disc herniations and in those with any disc pathology at both L4–L5 and L5–S1 levels. The intervertebral disc levels of the L4–L5 and L5–S1 discs with irregular articular plateaus were observed to have significantly more disc herniations among all patients.

Keywords

Intervertebral Disc, Intervertebral Disc Degeneration, Intervertebral Disc Displacement, Magnetic Resonance Imaging, Lumbosacral Region

DOI: 10.4328/ACAM.20731 Received: 2021-06-05 Accepted: 2021-08-19 Published Online: 2021-09-05 Printed: 2021-12-01 Ann Clin Anal Med 2021;12(12):1325-1331

Corresponding Author: Volkan Kızılgöz, Department of Radiology, Faculty of Medicine, Erzincan Binali Yıldırım University, Erzincan, Turkey.

E-mail: volkan.kizilgoz@erzincan.edu.tr P: +90 505 799 40 13

Corresponding Author ORCID ID: <https://orcid.org/0000-0003-3450-711X>

Introduction

Lumbar disc degeneration has been described in radiologic terms as decreased signal intensity on T2-weighted magnetic resonance imaging (MRI) with decreased space height [1]. An MRI study with histological correlation also showed that early disc degeneration may occur without any loss of disc height or decreased signal intensity on T2-weighted images [2]. Age is known to be an important factor in radiologically described disc degeneration [3]. The signal intensity, the height of the discs, and the combination of these parameters were found to be related to the disc degeneration [4–8]. Moreover, a relationship between the vertebral articular plateau shape and disc degeneration has been mentioned in the literature [9]. However, there is a lack of studies discussing the effect of the articular plateau surface type on disc degeneration and herniation. Thus, the current study uses the powerful tool of MRI to diagnose lumbar disc pathologies [10, 11], as the value of MRI in the assessment of lumbar discs and detection of disc herniations has been well documented in the literature [12].

The aim of this study is to reveal the possible association of the height of intervertebral disc spaces and types of vertebral articular surface with disc pathology. We also present the relationship between the level of disc degeneration and disc pathology on MRI. Moreover, all of these results are presented with regard to patient age groups.

Material and Methods

Patients

This was a retrospective cross-sectional study approved by the relevant ethics committee. Informed patient consent was waived by our institutional committee because of the study's retrospective nature. Data from patients admitted to our hospital for lumbar MRI between September 2018 and March 2019 were re-evaluated (n=850). Patients younger than 18 years old (n=11) were not included and only the MRI results of skeletally mature individuals were re-examined. Patients who had congenital pathologies (one patient with diastematomyelia, one patient with dural ectasia, and one patient with a tethered cord), infectious conditions (seven patients with lumbar discitis), or history of trauma (six patients with lumbar vertebra fracture) were excluded from the study. Patients who had undergone a disc operation (n=30) or who had scoliosis (Cobb angle of $\geq 20^\circ$; n=12), or the presence of internal fixation materials due to any kind of previous lumbar surgery (n=22) were also excluded. Patients with any kind of malignant neoplasm or vertebral lesion that affected the vertebral articular surface were also planned to be excluded from the study; however, there were no patients with such conditions among our sample. Moreover, five patients whose MRI results were not appropriate for examination because of motion artifacts were not included. Patients who met these exclusion criteria for any reason according to the MRI results were not included in the study. After exclusions, a total of 754 patients (445 female, 309 male; mean age: 45.66 ± 14.14 years) were enrolled. These patients were divided into three age groups before re-evaluation of MRI results: ≤ 25 years, between 26 and 40 years, and >40 years. The L4–L5 and L5–S1 intervertebral disc levels were evaluated

with regard to anterior, middle, and posterior intervertebral disc spaces; vertebral articular plateau geometry; intervertebral disc degeneration; and disc pathologies of the outer disc margins, representing disc herniation.

MRI Interpretation and Measurements

The heights of the anterior, middle, and posterior intervertebral disc spaces were measured. For each patient, the heights of intervertebral discs were measured as the distance between the anterior edges of the superior and inferior vertebral articular plateau, the distance between the posterior edges of the superior and inferior articular plateau, and the distance between two consecutive vertebral bodies at the midpoint of the anterior and posterior measurements (Figure 1).

The lumbar intervertebral discs were classified as bulging, protruding, or extruding according to the discs' outer margins. If more than one-quarter of the intervertebral disc circumference was displaced beyond the vertebral body margins, the disc was considered to be bulging. An intervertebral disc was considered to be protruding if the outer edges of the herniated part of the intervertebral disc were smaller than the measured distance at the base of the herniated part of the disc. If the distance measured between the edge of the herniated part of the intervertebral disc and the edge of the nonherniated part of the disc was greater than the length at the base of the herniation in at least one plane of the MRI, it was considered as a case of extrusion [13]. If no continuity was observed between the herniated disc material and the intervertebral disc itself (a sequestration), the disc was also considered to be extruding. Bulging was not accepted as a disc herniation in the current study.

To classify the vertebral body articular surfaces that were adjacent to the intervertebral discs, the terms concave, flat, and irregular were used. If most anterior and posterior edges of the articular plateau were higher than the deepest point of the articular surface for a superior articular plateau and concavity was observed on this surface in three consecutive midsagittal MRIs, the morphology was accepted as concave (the symmetrical shape being accepted as concave for the lower articular surface). If the end plate followed a straight line, the shape was classified as flat. If any surface irregularity was observed (e.g., cortical bumps, pits, or excrescences of the plateau surface), this morphology was classified as irregular. The articular plateau that deviated the most from concave was used for classification as irregular, flat, or concave. For instance, an intervertebral disc level with a concave lower articular surface and flat upper articular surface was considered as flat, whereas a disc level with a flat upper articular surface and irregular lower articular surface was considered as irregular (Figure 2).

The Pfirrmann grading method was used to evaluate lumbar disc degeneration on T2-weighted MRI [14] (Figure 3). The levels of disc degeneration were analyzed to determine possible relationships with disc space heights for each age group.

All quantitative and qualitative evaluations of MRI results were determined by the consensus of two reviewers, one a radiologist with 15 years of experience and the other an anatomist with 7 years of experience. The level of each lumbar intervertebral disc

was evaluated by both observers at the same time.

Statistical Analysis

The Kolmogorov–Smirnov test was used to analyze the homogeneity of data distributions for each dataset. Statistical analysis was performed to determine differences in intervertebral disc space heights between normal and pathological discs (bulging, protruding, and extruding). Moreover, the differences in disc space intervals between normal (nonherniated) discs (including normal and bulging discs) and herniated discs (including those with protrusion and extrusion) were calculated by Mann–Whitney U tests. Chi-square tests were used to compare these groups (normal and pathological, herniated and nonherniated) with regard to the morphological type of the articular plateau (concave, flat, and irregular). The relationship between disc space heights and disc degeneration levels was analyzed using the Kruskal–Wallis test. Detailed analyses (pairwise comparison tests) were conducted to determine the relationship between decreased intervertebral disc space height and each of the degeneration levels (represented by classes). All of the statistical analyses were performed using IBM SPSS 20 for Windows (IBM Corp.). In all statistical analyses, $p < 0.05$ represented a statistically significant difference.

Results

The relationships between the height of the intervertebral disc space of the L4–L5 level and disc pathologies are shown in Table 1. The anterior, middle, and posterior L4–L5 intervertebral disc space heights of normal and pathological discs (including disc bulging, protrusion, or extrusion) were compared for each age group, as also demonstrated in Table 1. The analysis showed that the middle intervertebral disc space height of the age group of 25–40 years, all height measurements of patients older than 40 years, and all L4–L5 intervertebral disc heights of all patients of any age groups with any disc pathology were significantly lower than the values obtained in the normal group. For the L5–S1 disc level, the anterior and middle intervertebral disc space heights of the age group of 25–40 years, all height measurements of patients older than 40 years, and all intervertebral disc heights of patients with disc pathologies were significantly lower than the values obtained for the patients without any disc pathology. The differences in the measurements of the intervertebral disc space height between normal (nonherniated) discs (including normal and bulging discs) and herniated discs were also evaluated. The anterior and middle height measurements of the age group of 25–40 years ($p < 0.01$), all height measurements of patients older than 40 years (for anterior height, $p = 0.02$ for the L4–L5 level and $p < 0.01$ for the L5–S1 level; for middle and posterior heights, $p < 0.01$), and all height values of all patients ($p < 0.01$) were significantly different between normal and herniated discs for both the L4–L5 and L5–S1 disc levels. Herniated discs had significantly lower height values than normal discs in these age groups.

The results of the morphological differences of the articular plateau in normal and pathological discs are shown in Table 2 and Table 3. For the L4–L5 disc level, irregular surfaces of the articular plateau were the cause of the significant differences in the age group of 25–40 years and among all patients as

Table 1. Differences between normal and pathological (including bulging, protruding, and extruding) discs with regard to intervertebral disc space height

	n	Height (mm)			Mean rank	p
		Median	Min	Max		
L4–L5 (age ≤ 25)						
Anterior height (normal)	50	10.9	5.8	13.9	36.4	0.78
Anterior height (disc pathology)	21	10.8	5.9	14.6	34.9	
Middle height (normal)	50	8.7	5.1	13.8	35.2	0.62
Middle height (disc pathology)	21	9.1	6.6	12.4	37.8	
Posterior height (normal)	50	5.8	2.6	8.7	37.2	0.44
Posterior height (disc pathology)	21	5.1	2.2	8.0	33.1	
L4–L5 (25 < age ≤ 40)						
Anterior height (normal)	111	10.3	5.3	12.3	126.4	0.16
Anterior height (disc pathology)	119	10.2	3.7	15.7	105.3	
Middle height (normal)	111	9.6	5.5	12.9	134.3	<0.01
Middle height (disc pathology)	119	8.7	0.7	14.1	97.9	
Posterior height (normal)	111	5.1	2.1	8.7	120.5	0.26
Posterior height (disc pathology)	119	5.1	2.1	8.7	110.8	
L4–L5 (age > 40)						
Anterior height (normal)	100	10.8	7.3	15.4	257.6	<0.01
Anterior height (disc pathology)	353	10.2	3.2	16.1	218.3	
Middle height (normal)	100	10.2	0.8	13.8	302.7	<0.01
Middle height (disc pathology)	353	8.7	0.8	14.1	205.5	
Posterior height (normal)	100	5.1	2.3	8.8	285.5	<0.01
Posterior height (disc pathology)	353	4.3	0.7	8.5	210.4	
L4–L5 (total)						
Anterior height (normal)	261	10.9	5.3	15.4	418.9	<0.01
Anterior height (disc pathology)	493	10.2	3.2	16.1	355.5	
Middle height (normal)	261	9.5	0.8	13.8	449.3	<0.01
Middle height (disc pathology)	493	8.7	0.7	14.1	339.4	
Posterior height (normal)	261	5.1	2.1	8.8	442.6	<0.01
Posterior height (disc pathology)	493	4.3	0.7	8.7	343.0	
L5–S1 (age ≤ 25)						
Anterior height (normal)	54	11.1	6.5	18.0	36.7	0.60
Anterior height (disc pathology)	17	11.1	3.3	13.7	33.7	
Middle height (normal)	54	7.8	3.3	13.4	35.1	0.54
Middle height (disc pathology)	17	8.5	4.6	11.4	38.6	
Posterior height (normal)	54	4.1	2.3	8.9	35.4	0.69
Posterior height (disc pathology)	17	4.6	2.2	6.7	37.7	
L5–S1 (25 < age ≤ 40)						
Anterior height (normal)	110	10.9	3.9	17.0	130.2	<0.01
Anterior height (disc pathology)	120	10.0	0.5	16.1	101.9	
Middle height (normal)	110	8.5	4.2	14.1	134.4	<0.01
Middle height (disc pathology)	120	7.6	3.6	12.1	98.1	
Posterior height (normal)	110	3.6	1.6	6.7	118.3	0.53
Posterior height (disc pathology)	120	3.6	1.0	8.1	112.9	
L5–S1 (age > 40)						
Anterior height (normal)	176	11.7	4.1	17.2	260.0	<0.01
Anterior height (disc pathology)	277	10.5	1.0	19.5	206.0	
Middle height (normal)	176	9.5	2.3	14.4	292.5	<0.01
Middle height (disc pathology)	277	7.5	1.0	16.0	185.3	
Posterior height (normal)	176	4.1	1.4	8.5	267.5	<0.01
Posterior height (disc pathology)	277	3.2	0.7	7.8	201.2	
L5–S1 (total)						
Anterior height (normal)	340	11.4	3.9	18.0	423.0	<0.01
Anterior height (disc pathology)	414	10.4	0.5	19.5	340.1	
Middle height (normal)	340	9.1	2.3	14.4	451.5	<0.01
Middle height (disc pathology)	414	7.5	1.0	16.0	316.6	
Posterior height (normal)	340	3.9	1.4	8.9	422.1	<0.01
Posterior height (disc pathology)	414	3.2	0.7	8.1	340.8	

Table 2. Cross-tabulation of articular plateau morphology versus disc pathologies at the L4–L5 level

Age group	Morphology	Normal	Disc pathology	Total	p	Age group	Morphology	Normal	Disc pathology	Total	p
≤25	C	35 (66.0%)	18 (34.0%)	53	0.06	25 < age ≤ 40	C	91 (51.1%)	87 (48.9%)	178	0.29
	F	15 (88.2%)	2 (11.8%)	17			F	18 (47.4%)	20 (52.6%)	38	
	IRG	0 (0.0%)	1 (100%)	1			IRG	2 (14.3%)	12 (85.7%)	14	
	Total	50	21	71			Total	111	119	230	
p-values for C vs. F: 0.674; C vs. IRG: 0.008; F vs. IRG: 0.030											
Age group	Morphology	Normal	Disc pathology	Total	p	Age group	Morphology	Normal	Disc pathology	Total	p
>40	C	83 (25.9%)	237 (74.1%)	320	<0.01	Total	C	209 (37.9%)	342 (62.1%)	551	<0.01
	F	8 (11.6%)	61 (88.4%)	69			F	41 (33.1%)	83 (66.9%)	124	
	IRG	9 (14.1%)	55 (85.9%)	64			IRG	11 (13.9%)	68 (86.1%)	79	
	Total	100	353	453			Total	261	493	754	
p-values for C vs. F: 0.011; C vs. IRG: 0.042; F vs. IRG: 0.670											

C, Concave; F, flat; IRG, irregular.

Table 3. Cross-tabulation for articular plateau morphology versus disc pathologies at the L5–S1 level

Age group	Morphology	Normal	Disc pathology	Total	p	Age group	Morphology	Normal	Disc pathology	Total	p
≤25	C	38 (79.2%)	10 (20.8%)	48	0.37	25 < age ≤ 40	C	98 (48.8%)	103 (51.2%)	201	0.19
	F	16 (69.6%)	7 (30.4%)	23			F	11 (50.0%)	11 (50.0%)	22	
	IRG	0 (0.0%)	0 (0.0%)	0			IRG	1 (14.3%)	6 (85.7%)	7	
	Total	54	17	71			Total	110	120	230	
Age group	Morphology	Normal	Disc pathology	Total	p	Age group	Morphology	Normal	Disc pathology	Total	p
>40	C	158 (44.0%)	201 (56.0%)	359	<0.01	Total	C	294 (48.4%)	314 (51.6%)	608	<0.01
	F	13 (25.0%)	39 (75.0%)	52			F	40 (42.1%)	57 (58.8%)	97	
	IRG	5 (11.9%)	37 (88.1%)	42			IRG	6 (12.2%)	43 (87.8%)	49	
	Total	176	277	453			Total	340	414	754	
p-values for C vs. F: 0.009; C vs. IRG: <0.001; F vs. IRG: 0.109											

C, Concave; F, flat; IRG, irregular.

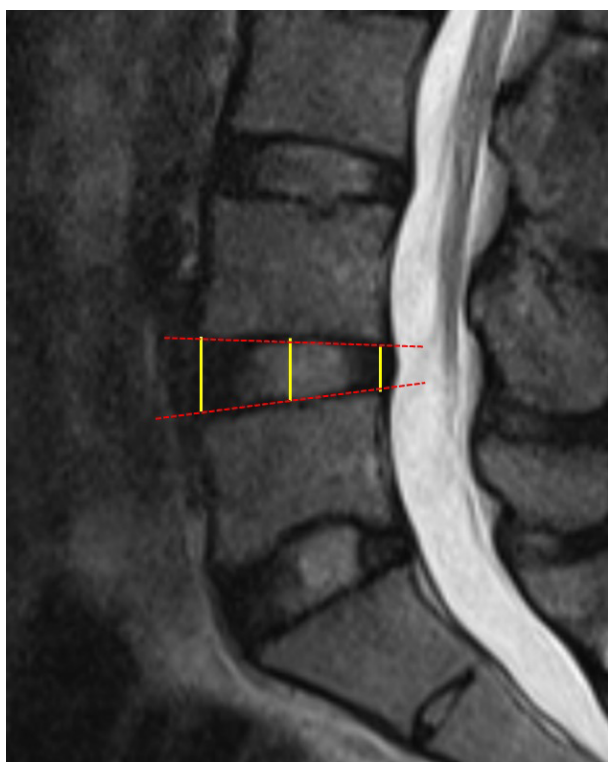


Figure 1. Intervertebral disc height measurements. The red dashed lines are drawn with respect to the end plate surfaces to determine the midpoint. Anterior, posterior, and middle intervertebral disc height measurements are shown with yellow lines.

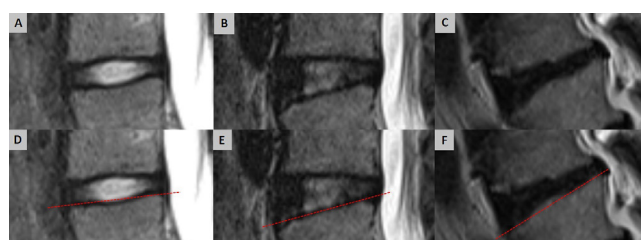


Figure 2. End plate classifications: (a) concave, (b) flat, (c) irregular, (d–f) end plate surfaces with the guidance of a straight line (red dashed line). The concavity is easily depicted by the straight line (d). The flat end plate surface follows the straight line (e). The irregular type has upper and lower surfaces shown with respect to the straight line (f).

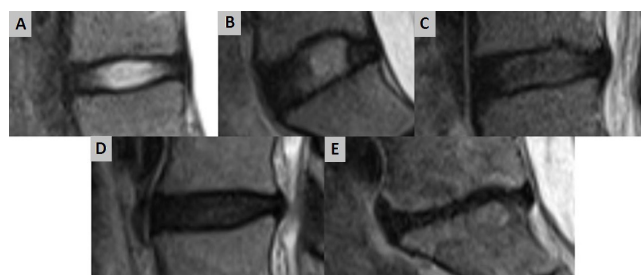


Figure 3. Grade I (A), grade II (B), grade III (C), grade IV (D), and grade V (E) intervertebral disc signal intensity on T2-weighted MRI, using the Pfirrmann classification.

shown by the chi-square test results of pairs. In the age group of >40 years, there were significantly more pathological discs in the flat and irregular groups than in the concave group. There was no significant difference in the number of pathological discs between the flat and irregular groups, however. At the L5–S1 disc level, there were more disc pathologies observed in the flat and irregular articular plateaus for the group of patients older than 40 years, and the irregular group had significantly more pathological discs than the concave or flat groups for all patients at this disc level.

The effect of articular plateau morphology on disc hernias was also investigated. Patients with flat articular plateaus had significantly more herniated discs than concave end plates among those older than 40 years ($p=0.031$), and patients with irregular articular plateaus had significantly more herniated discs than the concave group for all patients at the L4–L5 disc level ($p<0.01$). For the L5–S1 disc level, patients with irregularly shaped end plates had significantly more herniated discs when compared with other morphological types among patients >40 years old and among all patients at the L5–S1 disc level ($p<0.01$).

As the level of degeneration increased, the presence of disc pathology and herniation also increased significantly for all age groups for both L4–L5 and L5–S1 disc levels ($p<0.01$). The anterior, middle, and posterior intervertebral disc space heights were significantly lower for those with grade 5 degeneration in comparison with other degeneration classes, and grade 4 discs had significantly lower posterior height values in comparison with grade 1 discs at the L4–L5 level ($p<0.01$).

Discussion

This study focused on the L4–L5 and L5–S1 disc levels because disc herniations most often occur in the lumbosacral area. In the literature, it is stated that 75% of lumbar spinal flexion occurs at the lumbosacral joint, while 15% to 20% of lumbar flexion occurs at the L4–L5 level [15]. For this reason, the current study was designed to analyze the possible relationships between the intervertebral disc space heights of these levels and disc pathologies, because 90%–95% of clinically significant spinal radiculopathies are known to occur at the L4–L5 and L5–S1 levels [16].

The sum of the disc heights is generally accepted to be one-quarter of the total height of the vertebral column [17]. We investigated the effect of disc height on disc herniation, and the disc spaces were measured in light of the information provided in previous studies to evaluate these possible relationships. Some researchers have used converted measurements and ratios based on intervertebral disc heights instead of specifically measuring the intervertebral disc spaces in their studies [18, 19]. To determine anomalies in the morphological measurements of intervertebral disc spaces, an understanding of normal morphological values is required. Before discussing the results of the current study, the findings of previous research on the morphological properties of intervertebral disc spaces should be mentioned. Mirab et al. attempted to determine the normal intervertebral disc dimensions of Iranian participants. In their MRI study, they included 14 volunteers with normal intervertebral discs with an age range of 40–59 years

and reported mean values of anterior, middle, and posterior intervertebral heights of 18.14, 13.82, and 10.14 mm at the L4–L5 level and 18.71, 12.99, and 8.51 mm at the L5–S1 level, respectively [20]. The study by Hong et al. ($n=138$, age range of 15–25 years) aimed to reveal the normal intervertebral disc space of the Korean population. The anterior, middle, and posterior intervertebral space distances were 10.83, 10.05, and 7.20 mm at the L4–L5 level and 10.40, 9.58, and 6.02 at the L5–S1 level by MRI [18]. In the study by Kızılgöz and Ulusoy, the researchers used lateral lumbar spine radiography to determine the median anterior, middle, and posterior disc heights, which were 13.26, 11.20, and 8.44 mm for the L4–L5 level and 12.46, 9.50, and 5.89 mm for the L5–S1 level for non-degenerated lumbar discs [19]. In the current study, the median anterior, middle, and posterior intervertebral disc heights were measured as 10.9, 9.5, and 5.1 mm, respectively, for the L4–L5 level and 11.4, 9.1, and 3.9, respectively, for the L5–S1 level. The variations in these measurements might be the result of using different modalities; however, these differences may also reflect genetic variations among populations.

Intervertebral disc space height was another parameter investigated by some researchers as a possible morphological factor contributing to the difference between normal and herniated discs. The results of the research conducted by Kızılgöz and Ulusoy showed that anterior and posterior intervertebral disc space heights were associated with disc degeneration and disc herniation while middle intervertebral disc space height was associated with disc herniation at the L4–L5 level. However, that study was conducted using lateral lumbar radiography [19]. According to the results of Lee et al.'s MRI study, the anterior and middle heights of the intervertebral disc spaces were significantly lower for both degenerated and herniated discs in comparison with normal intervertebral discs at the L4–L5 level. That study was performed with a study population between the ages of 20 and 25 years [21]. In this current research, measurements of the L4–L5 and L5–S1 intervertebral disc space levels indicated a significant difference between those older than 40 years and the group of all patients, and the disc space was narrower for those with disc pathologies and disc herniation among these intervertebral disc levels.

Some other studies have investigated the shape of the end plates to determine their relationship with disc pathologies. In their case-control study, Pouriesa et al. measured the difference of end plates (DEP) [22]. In that study, DEP represented the difference between the anteroposterior diameters of the lower and upper end plates of the vertebral body adjacent to the intervertebral discs. The DEP measurements of herniated discs were significantly higher for the L4–L5 and L5–S1 levels in comparison with normal discs at those levels. Harrington et al. conducted a study among patients younger than 60 years using computed tomography scans and claimed that height, weight, and body mass index were not related to disc herniations at the L4–L5 and L5–S1 levels [23]. However, the shape of the vertebral body was related to disc herniation at these levels, and the authors claimed that more circular vertebral end plates showed a strong correlation with posterior intervertebral disc herniation in both men and women. He et

al. measured the concave angle of the vertebral end plate and investigated possible relationships with disc degeneration and disc herniation [24]. This angle was measured by T2 midsagittal MRI. For the superior end plate, the angle was formed by the line passing through the highest anterior point of the vertebral body and the deepest point of the end plate cavity and by the line passing through the highest posterior point of the vertebral body and the deepest point of the end plate cavity. The wider this concave angle, the flatter the vertebral end plate. They claimed that this angle increases with the presence of lumbar disc degeneration and that the degree of widening of this angle is related to the severity of disc degeneration. However, these authors found no relationship between this angle and lumbar intervertebral disc herniation.

The end plate surface is another morphological property that might be related to disc pathologies. Wang et al. classified the surface structure of vertebral end plates as concave, flat, and irregular [25]. According to the results of their study, the shape of the end plate varies considerably between the upper and lower lumbar regions. Moreover, end plates were found to be more concave in the upper lumbar region and more flat in lower lumbar areas. Another significant study by Pappou et al. indicated that intervertebral disc degeneration increased from concave to flat to an irregular end plate morphology. On the other hand, concave levels were associated with fewer degenerated discs and no difference was observed between flat and irregular levels for discs with a herniated nucleus pulposus [9]. In the current study, an irregular articular plateau was observed significantly more often in cases of disc pathologies for the L4–L5 and L5–S1 levels, and more disc herniations were found in the L5–S1 level.

The Pfirrmann grading system [14] is one of the most popular classifications used in the assessment of disc degeneration. Applying this method, we sought to determine the relationship between age and degeneration levels of intervertebral disks. As the degeneration grade of the discs increased, the presence of disc pathology and herniation also increased significantly for both the L4–L5 and L5–S1 disc levels of all age groups.

This study has some limitations. First, a larger sample size would be beneficial in order to obtain normal morphological values and to determine the differences between patient and control groups. In addition, the current patient sample was obtained from a single center, but multicenter studies might provide more accurate information and more statistical differences of larger populations with variabilities among different populations in terms of normal values, which might be explained by genetic differences. Second, MRI is considered to be the gold standard for the diagnosis of disc pathologies, but this could be considered as another limitation of the present investigation. The results of anatomical studies using cadaveric observations and measurements would provide a better understanding of the morphological differences between patient and control groups. Moreover, measurements and observations could have varied between the reviewers in this study, who investigated the possible anatomical risk factors for disc pathologies. There were few patients with irregularly shaped articular surfaces, and this might have possibly had an effect on the statistical analyses by preventing an accurate comparison of

the variations in the articular plateau as a risk factor for disc pathologies in patients in the younger age group. Finally, height, weight, and body mass index are other important parameters that might play roles in intervertebral disc space measurements and disc pathologies. Including these parameters alongside the morphological properties of the intervertebral disc space would provide more impactful results that could contribute to a better understanding of the risk factors of disc pathologies.

Conclusion

In this study, we have presented the normal intervertebral disc height values of a group of patients from a single center. In these patients, measurements of the intervertebral disc space of the L4–L5 and L5–S1 levels showed that among discs with pathologies or herniation, the intervertebral disc levels were narrower in patients older than 40 years as well as for all patients in total. Disc pathologies were more frequently observed in discs with an irregular articular plateau at the L4–L5 and L5–S1 levels, and more disc herniations were found at the L5–S1 level. Among patients of all ages, the presence of disc pathologies and disc herniations was observed much more frequently as the grade of disc degeneration increased.

Scientific Responsibility Statement

The authors declare that they are responsible for the article's scientific content including study design, data collection, analysis and interpretation, writing, some of the main line, or all of the preparation and scientific review of the contents and approval of the final version of the article.

Animal and human rights statement

All procedures performed in this study were in accordance with the ethical standards of the institutional and/or national research committee and with the 1964 Helsinki declaration and its later amendments or comparable ethical standards. No animal or human studies were carried out by the authors for this article.

Funding: None

Conflict of interest

None of the authors received any type of financial support that could be considered potential conflict of interest regarding the manuscript or its submission.

References

- Osborn AG. Normal aging and disk degeneration. In: Osborn AG, ed. *Diagnostic Neuroradiology*. St. Louis: Mosby, 1994: 836–40.
- Schiebler ML, Grenier N, Fallon M, Camerino V, Zlatkin M, Kressel HY. Normal and degenerated intervertebral disk: In vivo and in vitro MR imaging with histopathologic correlation. *Am J Roentgenol*. 1991; 157: 93–7.
- Luoma K, Vehmas T, Riihimäki H, Raininko R. Disc Height and Signal Intensity of the Nucleus Pulposus on Magnetic Resonance Imaging as Indicators of Lumbar Disc Degeneration. *Spine*. 2001; 26: 680–6
- Modic MT, Pavlicek W, Weinstein MA, Boumpfrey F, Ngo F, Hardy R et al. Magnetic resonance imaging of Intervertebral disk disease: Clinical and pulse sequence considerations. *Radiology*. 1984; 152: 103–11.
- Terti M, Paajanen H, Laato M, Aho H, Komu M, Kormanen M. Disc degeneration in magnetic resonance imaging: A comparative biochemical, histologic and radiologic study in cadaver spines. *Spine*. 1991; 16: 629–34.
- Riihimäki H, Mattson T, Zitting A, Wickström G, Hänninen K, Waris VP. Radiographically detectable degenerative changes of the lumbar spine among concrete reinforcement workers and house painters. *Spine*. 1990; 15: 114–9.
- Parkkola R, Kormanen M. Lumbar disc and back muscle degeneration on MRI: Correlation to age and body mass. *J Spinal Disord*. 1992; 5: 86–92.
- Videman T, Sarna S, Battie MC, Koskinen S, Gill K, Paananen H et al. The long term effects of physical loading and exercise lifestyles on back-related symptoms, disability, and spinal pathology among men. *Spine*. 1995; 20: 699–709.
- Pappou IP, Cammisa FP Jr, Girardi FP. Correlation of end plate shape on MRI and disc degeneration in surgically treated patients with degenerative disc disease and herniated nucleus pulposus. *Spine J*. 2007; 7(1): 32–8.
- Weiner BK, Patel R. The accuracy of MRI in the detection of Lumbar Disc Containment. *J Orthop Surg*. 2008; 3: 46. doi: 10.1186/1749-799X-3-46
- Tawa N, Rhoda A, Diener I (2016). Accuracy of magnetic resonance imaging in detecting lumbo-sacral nerve root compromise: a systematic literature review. *BMC Musculoskelet Disord*. 2016; 17(1): 386. doi: 10.1186/s12891-016-1236-z
- Yu WD, Williams SL. Spinal imaging. In: Spivak, Connelly, editor. *Orthopaedic Knowledge Update: Spine 3*. American Academy of Orthopaedic Surgeons, Chicago 2006

13. Fardon DF, Williams AL, Dohring EJ, Murtagh FR, Rothman SLG, Sze GK. Lumbar disc nomenclature: version 2.0: Recommendations of the combined task forces of the North American Spine Society, the American Society of Spine Radiology and the American Society of Neuroradiology. *Spine J.* 2014; 14(11): 2525–45. doi: 10.1016/j.spinee.2014.04.022
14. Pfirrmann CW, Metzdorf A, Zanetti M, Hodler J, Boos N. Magnetic resonance classification of lumbar intervertebral disc degeneration. *Spine.* 2001; 26(17): 1873–8. doi: <http://dx.doi.org/10.1097/00007632-200109010-00011>
15. Alter MJ. *Science of flexibility. Third Edition, Human Kinetics, Champaign pp: 239. 2004.*
16. Deyo RA, Weinstein DO. Low back pain. *N Engl J Med.* 2001; 344(5): 363–70.
17. Alomari RS, Corso JJ, Chaudhary V and Dhillon G. Computer-aided diagnosis of lumbar disc pathology from clinical lower spine MRI. *Int J Comput Assist Radiol Surg.* 2010; 5(3): 287–93. doi: 10.1007/s11548-009-0396-9
18. Hong CH, Park JS, Jung KJ and Kim WJ. Measurement of the normal lumbar intervertebral disc space using magnetic resonance imaging. *Asian Spine J.* 2010; 4(1): 1–6. doi: 10.4184/asj.2010.4.1.1
19. Kızılgöz V, Ulusoy GR. Is there any relationship between lumbar intervertebral disc space height and lumbar disc herniations? A study of radiographic evaluation. *The Journal of Turkish Spinal Surgery.* 2019; 30(3), 187–92
20. Mirab SMH, Barbarestani M, Tabatabaei SM, Shahsavari S, Minaeii Zangi MB. Measuring Dimensions of Lumbar Intervertebral Discs in Normal Subjects. *Anatomical Sciences.* 2017; 14(1): 3–8.
21. Lee K, Shin JS, Lee J, Lee YJ, Kim MR, Seong I et al. Lumbar intervertebral disc space height in disc herniation and degeneration patients aged 20 to 25. *Int J Clin Exp Med.* 2017; 10(4): 6828–36.
22. Pouriesia M, Fouladi RF, Mesbahi S. Disproportion of end plates and the lumbar intervertebral disc herniation. *Spine J.* 2013; 13(4):402–7 doi: 10.1016/j.spinee.2012.11.047
23. Harrington JF, Sungarian A, Rogg J, Makker VJ, Epstein MH. The Relation Between Vertebral Endplate Shape and Lumbar Disc Herniations. *Spine.* 2001; 26(19): 2133–8
24. He X, Liang A, Gao W, Peng Y, Zhang L, Liang G et al. The relationship between concave angle of vertebral endplate and lumbar intervertebral disc degeneration. *Spine.* 2012; 37(17): E1068–E1073
25. Wang Y, Battie MC, Videman T. A morphological study of lumbar vertebral endplates: radiographic, visual and digital measurements. *European Journal of Spine.* 2012; 21: 2316–23

How to cite this article:

Volkan Kızılgöz, Muhammet Bora Uzuner. Influence of lumbar intervertebral disc height and geometry of the articular plateau surface on disc pathologies. *Ann Clin Anal Med* 2021;12(12):1325-1331